

## AN OUTBREAK OF EOSINOPHILIC MENINGITIS CAUSED BY *ANGIOSTRONGYLUS CANTONENSIS* IN TRAVELERS RETURNING FROM THE CARIBBEAN

TREVOR J. SLOM, M.D., MARGARET M. CORTESE, M.D., SUSAN I. GERBER, M.D., RODERICK C. JONES, M.P.H., TIMOTHY H. HOLTZ, M.D., M.P.H., ADRIANA S. LOPEZ, M.H.S., CARLOS H. ZAMBRANO, M.D., ROBERT L. SUFIT, M.D., YUWAPORN SAKOLVAREE, M.Sc., WANPEN CHAICUMPA, Ph.D., BARBARA L. HERWALDT, M.D., M.P.H., AND STUART JOHNSON, M.D., D.T.M.&H.

### ABSTRACT

**Background** Outbreaks of eosinophilic meningitis caused by the roundworm *Angiostrongylus cantonensis* are rarely reported, even in regions of endemic infection such as Southeast Asia and the Pacific Basin. We report an outbreak of *A. cantonensis* meningitis among travelers returning from the Caribbean.

**Methods** We conducted a retrospective cohort study among 23 young adults who had traveled to Jamaica. We used a clinical definition of eosinophilic meningitis that included headache that began within 35 days after the trip plus at least one of the following: neck pain, nuchal rigidity, altered cutaneous sensations, photophobia, or visual disturbances.

**Results** Twelve travelers met the case definition for eosinophilic meningitis. The symptoms began a median of 11 days (range, 6 to 31) after their return to the United States. Eosinophilia was eventually documented in all nine patients who were hospitalized, although on initial evaluation, it was present in the peripheral blood of only four of the nine (44 percent) and in the cerebrospinal fluid of five (56 percent). Repeated lumbar punctures and corticosteroid therapy led to improvement in symptoms in two of three patients with severe headache, and intracranial pressure decreased during corticosteroid therapy in all three. Consumption of one meal ( $P=0.001$ ) and of a Caesar salad at that meal ( $P=0.007$ ) were strongly associated with eosinophilic meningitis. Antibodies against an *A. cantonensis*-specific 31-kD antigen were detected in convalescent-phase serum samples from 11 patients.

**Conclusions** Among travelers at risk, the presence of headache, elevated intracranial pressure, and pleocytosis, with or without eosinophilia, particularly in association with paresthesias or hyperesthesias, should alert clinicians to the possibility of *A. cantonensis* infection. (N Engl J Med 2002;346:668-75.)

Copyright © 2002 Massachusetts Medical Society.

**A**NGIOSTRONGYLUS *cantonensis*, the rat lungworm, is the most common infectious cause of eosinophilic meningitis in humans.<sup>1</sup> Rats serve as the definitive hosts of the nematode (roundworm), whereas humans become infected by ingesting third-stage larvae in raw or inadequately cooked intermediate hosts, such as snails

and slugs, or transport hosts, such as freshwater prawns, frogs, fish, and planarians.<sup>2-5</sup> Infection may also be acquired by the consumption of fresh produce, such as lettuce, contaminated with these intermediate or transport hosts.<sup>4,6</sup>

When third-stage larvae are ingested by humans, they penetrate the vasculature of the intestinal tract and eventually reach the meninges, where they usually die shortly thereafter. An eosinophilic reaction develops in response to the dying larvae and is manifested as aseptic meningitis. Although most cases of infection are self-limited,<sup>7</sup> neurologic sequelae develop in some cases, and deaths have been reported.<sup>6,8-10</sup>

Most cases of *A. cantonensis* meningitis have been reported in Southeast Asia and the Pacific Basin,<sup>1,11</sup> but sporadic cases have been reported in many other regions.<sup>12-16</sup> Although most cases occur singly, outbreaks have also been reported.<sup>1,10,17</sup> Reports from the continental United States and the Caribbean include one case in New Orleans,<sup>18</sup> multiple cases in Cuba,<sup>19-21</sup> and one possible case in Jamaica that was diagnosed on the basis of clinical criteria.<sup>22</sup> We describe a large outbreak of *A. cantonensis*-associated eosinophilic meningitis among a group of U.S. travelers returning from Jamaica.

### METHODS

#### Description of Outbreak

On April 29, 2000, two medical students were hospitalized in Chicago with a 10-day history of progressively worsening headache, neck pain, and paresthesias. These students had been part of a group of 23 travelers from three states who had visited Jamaica from April 2 through April 9. Results of the analysis of their cerebrospinal fluid were consistent with the presence of aseptic meningitis; one patient had 36 percent eosinophils. Over the next week and a half, seven fellow travelers from two states were hospitalized with meningitis.

From the Departments of Infectious Diseases (T.J.S., C.H.Z., S.J.) and Neurology (R.L.S.), Northwestern University Medical School, Chicago; the Epidemic Intelligence Service, Epidemiology Program Office (M.M.C., T.H.H.), and the Division of Parasitic Diseases (T.H.H., A.S.L., B.L.H.), Centers for Disease Control and Prevention, Atlanta; the Chicago Department of Public Health, Chicago (S.I.G., R.C.J.); the Atlanta Research and Education Foundation, Atlanta (A.S.L.); the Faculty of Tropical Medicine, Mahidol University, Bangkok, Thailand (Y.S., W.C.); and the Veterans Affairs Chicago Health Care System, Lakeside Division, Chicago (S.J.). Address reprint requests to Dr. Johnson at the Medicine Service, VA Chicago HCS-Lakeside, 333 East Huron, Chicago, IL 60611, or at stu-johnson@northwestern.edu.

### Identification and Clinical Description of Cases

After hospitalization of the 2 index patients, the other 21 travelers were instructed to seek medical attention if they had any of the following: headache, neck pain, and altered cutaneous sensations. A case of eosinophilic meningitis was clinically defined as the acute onset of headache, within 35 days after the patient had returned from Jamaica, accompanied by at least one of the following: visual disturbances, photophobia, nuchal rigidity, neck pain, hyperesthesias, and paresthesias. Eosinophilia was defined by the finding of at least 10 percent eosinophils in the total white-cell count in cerebrospinal fluid or at least 600 eosinophils per cubic millimeter in peripheral blood.

### Serologic Analysis

Paired samples obtained during the acute phase of the illness and again during convalescence were tested for antibodies against *A. cantonensis* with use of a Western blot technique and crude antigen prepared from young adult worms recovered from the brains of infected rats.<sup>23</sup> The presence of antibodies against the 31-kD antigen of *A. cantonensis* has been reported to be specific for the diagnosis of *A. cantonensis* infection,<sup>23</sup> although some cross-reactivity may be seen with *Trichinella spiralis* infection.<sup>24</sup> Acute-phase specimens were obtained within 1 week after hospitalization of the two index patients (23 to 26 days after they returned from Jamaica). Convalescent-phase specimens were obtained approximately 1 month after the acute-phase specimens (52 to 60 days after the patients had returned from Jamaica).

To exclude other possible causes of eosinophilic meningitis, we used enzyme immunoassays to test serum samples for antibodies against *Strongyloides stercoralis*, toxocara species, and *T. spiralis*.<sup>25</sup> Specimens that had a low level of reactivity in the trichinella immunoassay were also tested with the use of bentonite flocculation.

### Cohort Study

To identify risk factors for eosinophilic meningitis, we interviewed all travelers twice, using structured questionnaires that provided information about symptoms and potentially relevant exposures in Chicago, on the flights to and from Jamaica, and in Jamaica. For the second interview, menus from the restaurants the travelers had patronized in Jamaica were used to facilitate their recall of specific food items. Data were analyzed in Epi Info software (version, 6.04b,

Centers for Disease Control and Prevention, Atlanta). Risk ratios and P values were calculated with use of the two-tailed Fisher's exact test.

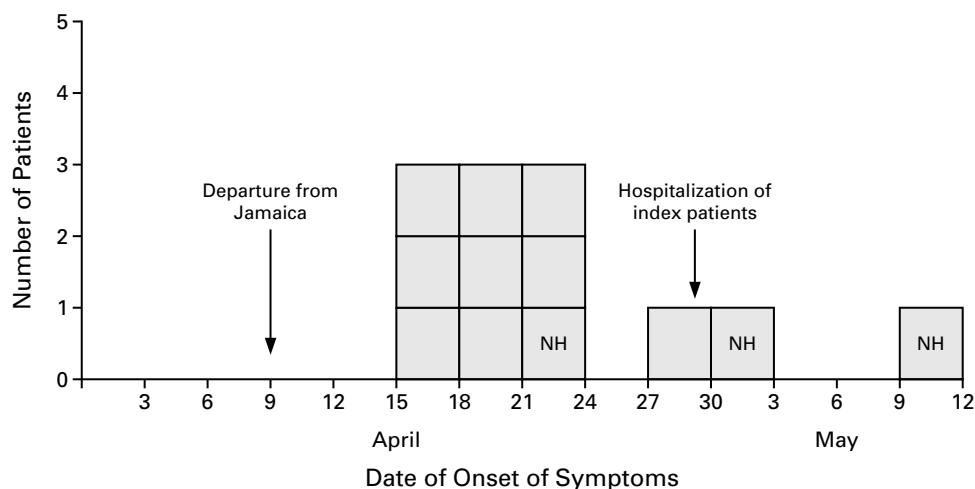
### Additional Investigations

On the basis of data obtained from the first round of interviews, investigators visited Jamaica in mid-May 2000 to determine which foods had been served at the restaurants patronized by the travelers, the sources of the foods of interest, and procedures for the procurement and handling of food used by these restaurants and their distributors. Patrons of the restaurant where the infection was most likely acquired — specifically, those who ate there on April 8 (the date of the implicated meal) or who ate a Caesar salad there between April 6 and 10 and who paid by credit card or who ate with someone who did — were contacted to determine what they had eaten and whether they had become ill. With the assistance of the local health authorities, we attempted to identify other cases of eosinophilic meningitis that had occurred in Jamaica by reviewing medical records of unexplained cases of meningitis at seven hospitals in various parts of Jamaica.

## RESULTS

### Patients and Clinical Course

Twelve of the 23 travelers (52 percent) met the case definition for eosinophilic meningitis. Nine of the 12 were hospitalized. The median time from departure from Jamaica to the onset of symptoms in the 12 patients was 11 days (range, 6 to 31) (Fig. 1). All 12 patients had a headache, since this was part of the case definition; visual disturbances or photophobia, neck pain or nuchal rigidity, and fatigue were the most common accompanying symptoms (Table 1). Hyperesthesias or paresthesias of the trunk or arms and legs (or all three) were reported by 9 of the 12 patients. Five patients reported having had a fever, but only two of the nine patients who were hospitalized had documented temperatures of more than 37.8°C.



**Figure 1.** Date of Onset of Symptoms in 12 Travelers with Eosinophilic Meningitis Who Left Jamaica on April 9, 2000. Each box represents one patient. Nine patients were hospitalized between April 29 (the date the two index patients were hospitalized) and May 3. NH denotes the nonhospitalized patients.

All nine hospitalized patients underwent lumbar punctures; lumbar puncture was not performed in the three patients who were not hospitalized. Among the hospitalized patients, four (44 percent) had peripheral-blood eosinophilia and five (56 percent) had cerebrospinal fluid eosinophilia on initial evaluation. Eosinophilic meningitis was eventually documented by examination of cerebrospinal fluid in eight of the nine hospitalized patients. Initial cerebrospinal fluid values are given in Table 2. Parasitic larvae were not identified in the cerebrospinal fluid specimens from seven patients that were examined microscopically.

Seven patients had peripheral-blood white-cell counts and differential counts determined on admission to the hospital (23 to 25 days after they had left Jamaica), at the midpoint of the clinical course (32 to 42 days after their departure), and after the resolution of symptoms (53 days after their departure). The mean ( $\pm$ SE) eosinophil count was significantly higher at the midpoint of the clinical course ( $957 \pm 203$  cells per cubic millimeter) than during the acute phase ( $443 \pm 90$  cells per cubic millimeter,  $P=0.03$  by the paired t-test) and convalescent phase ( $286 \pm 60$  cells per cubic millimeter,  $P=0.03$  by the paired t-test). The total pe-

ripheral-blood white-cell count did not, however, vary significantly over time.

Additional diagnostic tests included computed tomography (CT) of the brain in four patients and magnetic resonance imaging (MRI) of the brain in three of these four patients. CT in one patient showed a faint area of increased attenuation in the left cerebellar region, but the MRI showed generalized leptomeningeal enhancement, as has previously been shown in patients with neuroangiostrongyliasis.<sup>26-28</sup> Ophthalmologic assessment of another patient, who had transient loss of vision in the right temporal field, showed mild papilledema, but the results of CT and MRI of the brain were normal. The results of brain scans of the other two patients were normal.

For the treatment of headaches, seven patients were given opioid analgesic agents, with or without nonsteroidal antiinflammatory drugs, and the other five patients obtained relief with nonsteroidal antiinflammatory drugs alone. The three patients with the most severe symptoms underwent repeated lumbar punctures and received corticosteroids. After corticosteroid treatment, two of these three patients had a marked improvement in symptoms. The opening cerebrospi-

**TABLE 1.** EPIDEMIOLOGIC AND CLINICAL CHARACTERISTICS OF 23 TRAVELERS RETURNING FROM JAMAICA.

CHARACTERISTIC	PATIENTS (N=12)	TRAVELERS WHO DID NOT BECOME ILL (N=11)
Male sex — no. (%)	9 (75)	4 (36)
Age — yr		
Median	22	23
Range	21–28	22–26
Medical student — no. (%)	10 (83)	8 (73)
Chicago-area resident — no. (%)	10 (83)	9 (82)
Symptoms — no. (%)		
Headache	12 (100)	0
Visual disturbance or photophobia	11 (92)	0
Nuchal rigidity or neck pain	10 (83)	0
Fatigue	10 (83)	0
Hyperesthesias	9 (75)	0
Vomiting	8 (67)	0
Paresthesias	6 (50)	0
Muscle pain	6 (50)	0
Fever*	5 (42)	0
Muscle weakness	4 (33)	0
Diarrhea	2 (17)	0
Time from departure from Jamaica to onset of symptoms — days		
Median	11	
Range	6–31	

\*Only two of the nine patients who were hospitalized had documented temperatures of more than 37.8°C.

**TABLE 2.** INITIAL CEREBROSPINAL FLUID VALUES IN NINE PATIENTS WHO WERE HOSPITALIZED WITH EOSINOPHILIC MENINGITIS.\*

VARIABLE	MEDIAN	RANGE
Opening pressure (cm of water)†	24	12–55
White-cell count (cells/mm <sup>3</sup> )	333	18–765
Differential count (%)		
Lymphocytes	73	41–88
Eosinophils	13	0–54
Monocytes	8	4–22
Basophils	0	0–6
Polymorphonuclear leukocytes	0	0–4
Total protein (mg/dl)	52	36–82
Glucose (mg/dl)‡	55	51–81

\*Three of the nine patients underwent multiple lumbar punctures. The results from their first lumbar puncture were used to calculate the median and range. All nine hospitalized patients met the clinical case definition for eosinophilic meningitis, but one of the patients who underwent a single lumbar puncture did not have laboratory confirmation of cerebrospinal fluid eosinophilia (the cerebrospinal white-cell count in this patient was 215 cells per cubic millimeter, with 2 percent eosinophils, 88 percent lymphocytes, 2 percent polymorphonuclear leukocytes, and 8 percent monocytes).

†These results are based on values from six patients; the opening pressure was not recorded during lumbar puncture in three patients.

‡To convert values for glucose to millimoles per liter, multiply by 0.05551.

nal fluid pressure decreased in all three during corticosteroid therapy (Fig. 2).

The symptoms ultimately resolved in all 12 patients, although 8 (67 percent) had headaches for at least four weeks; 2 of these 8 had protracted headaches lasting six to eight weeks after hospital discharge. One patient still had a fine resting tremor of the arms and legs six months after the onset of the illness. Six patients (50 percent) missed more than three weeks of school or work.

#### Serologic Analysis

Antibodies against the 31-kD antigen of *A. cantonensis* were present on Western blot analysis of both the acute-phase and the convalescent-phase serum samples from 1 patient (8 percent) and of the convalescent-phase serum sample alone in 10 patients (83 percent) (Fig. 3) but in none of the acute-phase or convalescent-phase specimens from the 11 other travelers. The serum samples from 1 patient and from all 11 travelers who did not become ill were negative. None of the 21 travelers whose serum specimens were tested (including samples obtained during convalescence from all 12 patients) had serologic evidence of infection with *T. spiralis* or toxocara species. Serum specimens from two patients reacted in the immunoassay for antibodies against *S. stercoralis*; one of these samples had a low level of reactivity.

#### Retrospective Cohort Study

Results from both rounds of interviews showed that eating a particular meal at a restaurant in northwestern Jamaica the night before departure for the United States was associated with a significant risk of illness. Of seven restaurants where at least half the travelers ate, only two were patronized by all 12 patients. Only one restaurant meal was eaten by all 12 patients. Twelve of the 16 travelers who ate this meal became ill, whereas none of the 7 who did not eat this meal became ill (risk ratio, undefined;  $P=0.001$ ). All 12 patients reported eating Caesar salad at the meal, and this was the only item associated with a significant risk of illness (12 of the 13 who ate the salad became ill, as compared with none of the 3 who did not; risk ratio, undefined;  $P=0.007$ ). None of the travelers reported having eaten snails, slugs, or raw or inadequately cooked fish or shellfish during the trip.

#### Additional Investigations

The Caesar salad at the meal associated with illness included romaine lettuce, which had reportedly been washed, and canned, salted anchovies but no mollusks or other seafood. The salad bowl was placed on a plate and passed around the table. Whether locally grown parsley was used to garnish the plate was not known.

The romaine lettuce had been imported from the United States, and no obvious modes of contamination of the lettuce were identified when we visited the restaurant and the U.S. and Jamaican distributors of the lettuce.

Through credit-card records, we identified one additional person who was not part of this group of travelers and who ate Caesar salad at the restaurant on April 6 and who began to have headaches at an unspecified time thereafter. However, serologic testing was negative for antibodies against the 31-kD *A. cantonensis* antigen. No cases of eosinophilic meningitis were identified through a review of medical records in Jamaica.

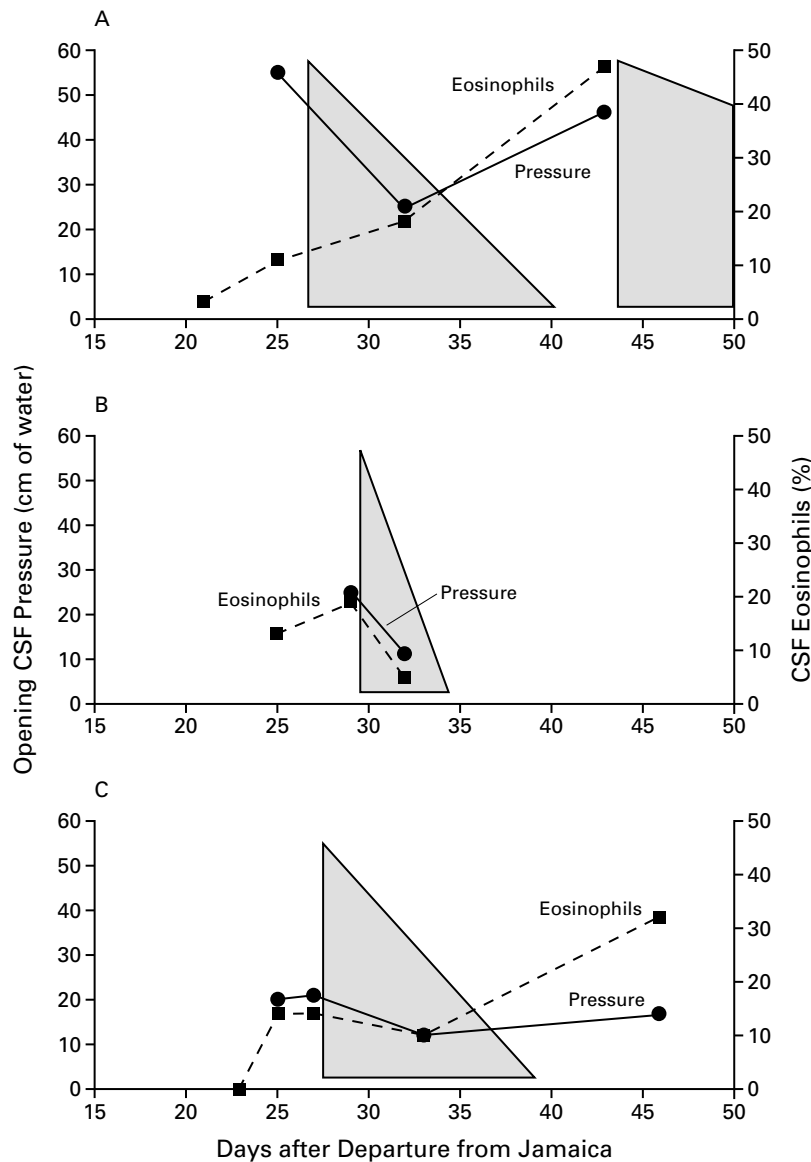
#### DISCUSSION

Infection with *A. cantonensis* has seldom been documented in the Western Hemisphere, and no outbreaks have been reported outside of Southeast Asia and the Pacific Basin. Although the 12 cases of infection that we described were not parasitologically confirmed, the combination of the clinical manifestations<sup>7</sup> and serologic data provides strong evidence that *A. cantonensis* was the etiologic agent of the outbreak. Antibodies against the 31-kD antigen have been documented in parasitologically confirmed cases of *A. cantonensis* infection but not in infections with *Gnathostoma spinigerum*, which can also cause eosinophilic meningitis.<sup>23,24</sup>

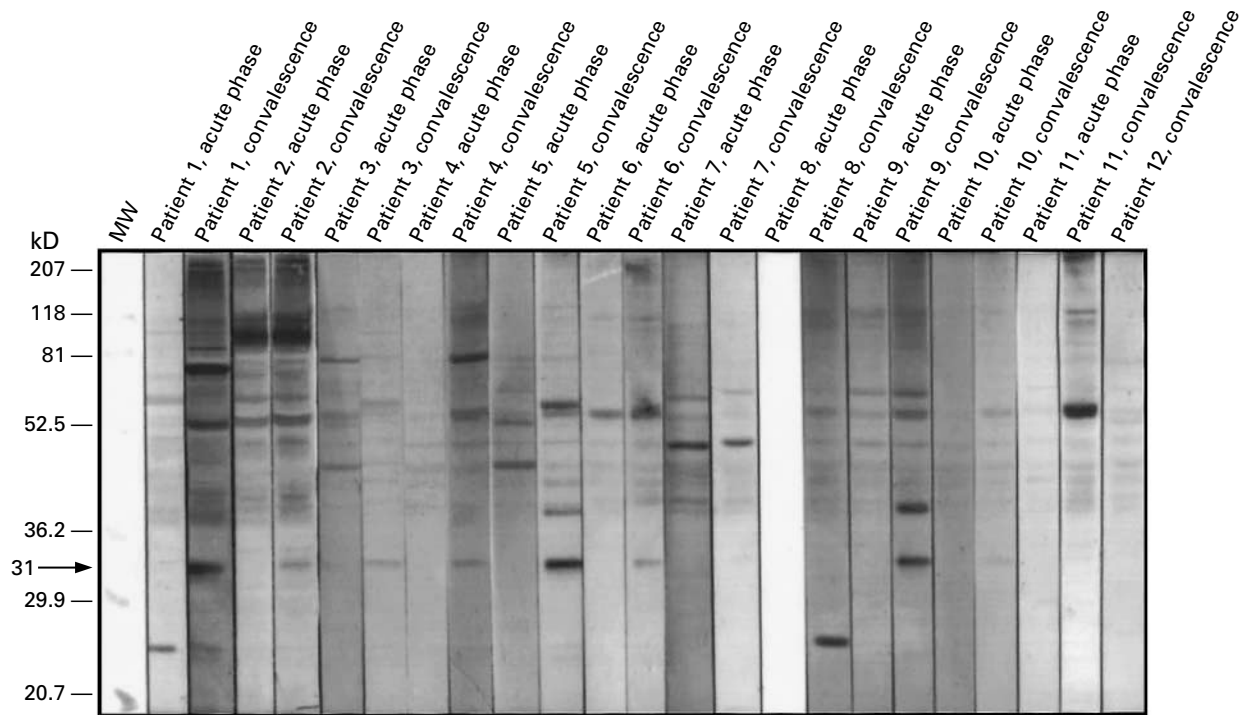
Several clinical and laboratory features of this outbreak are noteworthy. Eosinophilia, either in peripheral blood or cerebrospinal fluid, was not always present on initial laboratory testing. The peripheral-blood eosinophilia peaked five weeks after the presumed exposure, when symptoms were improving in most of the patients. Cases of *A. cantonensis* meningitis may be incorrectly ascribed to other causes of aseptic meningitis if eosinophilia is not present on initial testing.

Severe, persistent headache was the most prominent symptom among the patients who were hospitalized in this outbreak. This was probably due to the elevated intracranial pressure, which was documented at least once in eight of the nine patients who underwent lumbar punctures; four of the eight underwent CT and had normal-sized ventricles.

The clinical manifestations were similar to those described in Thailand<sup>7</sup> but different from those described in Taiwan.<sup>28,29</sup> The cases reported in Taiwan were more likely to involve children, to be associated with fever and encephalitis, and to have *A. cantonensis* larvae recovered from cerebrospinal fluid specimens. The reasons for these differences are unknown but may involve several factors: infection with a higher parasitic inoculum because of the large number of larvae typically found in the local intermediate host, *Achatina fulica*, the giant African snail; the use of a



**Figure 2.** Opening Cerebrospinal Fluid (CSF) Pressures in Three Patients with Eosinophilic Meningitis and Severe Symptoms Who Underwent Serial Lumbar Punctures and Received Corticosteroid Therapy. The periods of treatment with a corticosteroid and subsequent tapering of the dose are indicated by the shaded areas. The percentage of eosinophils in cerebrospinal fluid is also shown. The opening cerebrospinal fluid pressure decreased during corticosteroid treatment in all three patients. One of the patients (Panel A) had dramatic relief of his headache after the first two lumbar punctures. Both times, however, the headache had returned to the same level of intensity by the next morning. Therefore, dexamethasone was started the day after the second lumbar puncture (the initial regimen consisted of 6 mg given intravenously every 6 hours), with a dramatic and sustained improvement in symptoms over the next 12 to 24 hours. Three days after dexamethasone therapy was discontinued, the patient was readmitted with severe headache and projectile vomiting. The headache again resolved after dexamethasone treatment, and the dose was tapered more gradually. The headache resolved in another patient (Panel B) when corticosteroid therapy was given after the second lumbar puncture, but it did not resolve in a third patient (Panel C), despite four subsequent lumbar punctures and a 10-day trial of dexamethasone therapy.



**Figure 3.** Reactivity of Serum Obtained during the Acute Phase and Convalescent Phase to Crude Antigens from Adult *Angiostrongylus cantonensis* Worms in the 12 Patients with Eosinophilic Meningitis.

An arrow indicates the *A. cantonensis*-specific 31-kD band identified by Western blot analysis. Reactivity to this band was present in the convalescent-phase serum samples of Patients 1 through 11 as well as in the acute-phase specimen of Patient 3. Although not apparent in this figure, weakly reactive 31-kD bands were present on the freshly prepared Western blot strips of the convalescent-phase specimens of Patients 7, 8, and 11. Two of the three nonhospitalized patients (Patients 9 and 10) had serum reactivity to the 31-kD antigen. This finding supports the clinical case definition, since these patients did not undergo lumbar punctures or have laboratory confirmation of meningitis. The clinical courses of Patients 1, 5, and 11 are depicted in Figures 2A, 2C, and 2B, respectively. MW denotes the molecular-weight markers.

pumping technique to increase the volume of cerebrospinal fluid obtained from the subarachnoid space for diagnostic purposes<sup>28</sup>; or possibly, the strain of *A. cantonensis* involved.<sup>30</sup> Similar to the patients described in the reports from Thailand, the patients in our series were adults with low-grade fever or no fever and little evidence of encephalitis or obtundation.

We did not treat our patients with anthelmintic agents because of the theoretical possibility of exacerbating neurologic symptoms as a result of the death of larvae in the central nervous system<sup>6</sup> and the reported lack of efficacy of anthelmintic therapy for *A. cantonensis* infection in adult patients.<sup>10</sup> Most of our patients had a response to conservative management. However, three patients with persistent and severe headaches were subsequently treated with serial lumbar punctures and corticosteroid therapy. These interventions provided symptomatic relief for two of the patients but had no discernible effect in the third patient. The third

patient had cerebrospinal fluid opening pressures that were lower than those of the other two patients.

Corticosteroid therapy was recently shown to provide symptomatic relief of headaches caused by eosinophilic meningitis in a placebo-controlled, double-blind clinical trial that included 129 Thai patients.<sup>31</sup> Although optimal treatment of *A. cantonensis* meningitis has not been determined, many patients can be treated with supportive therapy alone. Repeated lumbar punctures and the use of corticosteroid therapy may be beneficial in patients with more severe symptoms.

The exact vehicle of transmission in this outbreak remains unclear. The meal eaten the night before departure for the United States was associated with a strong risk of illness, as was consumption of the Caesar salad at this meal; the lettuce was the salad ingredient that was most likely contaminated. The travelers remembered the salad well because it was prepared at

the table. Therefore, recall bias may have influenced the travelers' recollections. The possibility that some unrecognized, common exposure caused the outbreak cannot be excluded. Whether the outbreak affected other persons besides those in this group of travelers is unknown. Other cases could have been missed because they did not cause severe illness or were not thoroughly evaluated.

Since this outbreak, *A. cantonensis* has been identified in both rats and land snails in Jamaica.<sup>32</sup> The occurrence of the complete life cycle of *A. cantonensis* in Jamaica supports the hypothesis that the vehicle of this outbreak could have been contaminated in Jamaica, but it does not exclude the possibility of contamination in the United States, which was the source of the romaine lettuce used in the Caesar salad.

Regions where *A. cantonensis* infection is endemic clearly extend beyond Southeast Asia and the Pacific Basin.<sup>1</sup> Physicians and public health officials should be alert for this condition throughout the Caribbean and nearby regions, since *A. cantonensis* has been found in rats in Cuba,<sup>33</sup> Puerto Rico,<sup>34</sup> the Bahamas,<sup>35</sup> the Dominican Republic,<sup>36</sup> and Jamaica, as well as in New Orleans.<sup>37</sup> Headache, elevated intracranial pressure, and a nonneutrophilic pleocytosis, with or without eosinophilia, should suggest the possibility of *A. cantonensis* infection. The association of meningitis with paresthesias or hyperesthesias should also suggest this diagnosis, because these symptoms are unusual in other forms of meningitis. The usual advice travelers are given to prevent diarrheal disease<sup>38</sup> should also protect them against infection with *A. cantonensis*. In particular, we would advise travelers to and residents of the Caribbean to avoid eating unwashed fresh produce, such as lettuce, and undercooked or raw foods, such as snails and other mollusks.

We are indebted to the following persons for their help with this investigation: Julia A. Bonner, M.D., John Longano, M.D., Deanna Ashley, M.B., B.S., D.P.H., D.M., Colette Cunningham-Myrie, M.B., B.S., M.P.H., Peter Knight, M.P.H., Sheila Campbell-Forestier, M.B., B.S., D.P.H., Alex Konstantinov, M.D., Barry G. Campbell, Ph.D., John R. Warren, M.D., Mahouba Abdulla, Ellen M. Wallace, B.S., M.T.(A.S.C.P.), Susanna Partridge, B.S.Ed., Marianna Wilson, M.S., Jennifer Whitmon, M.S., Julio Fernandez, M.C., Aleksander U. Kalnins, B.A., and Steven M. Wolinsky, M.D.

## REFERENCES

- Kliks MM, Palumbo NE. Eosinophilic meningitis beyond the Pacific Basin: the global dispersal of a peridomestic zoonosis caused by *Angiostrongylus cantonensis*, the nematode lungworm of rats. *Soc Sci Med* 1992;34:199-212.
- Rachford FW. Potential intermediate and paratenic hosts for *Angiostrongylus cantonensis*. *J Parasitol* 1975;61:1117-9.
- Wallace GD, Rosen L. Studies on eosinophilic meningitis. IV. Experimental infection of fresh-water and marine fish with *Angiostrongylus cantonensis*. *Am J Epidemiol* 1967;85:395-402.
- Rosen L, Loison G, Laigret J, Wallace GD. Studies on eosinophilic meningitis. 3. Epidemiologic and clinical observations on Pacific islands and the possible etiologic role of *Angiostrongylus cantonensis*. *Am J Epidemiol* 1967;85:17-44.
- Ash LR. Observations on the role of mollusks and planarians in the transmission of *Angiostrongylus cantonensis* infection to man in New Caledonia. *Rev Biol Trop* 1976;24:163-74.
- Bowden DK. Eosinophilic meningitis in the New Hebrides: two outbreaks and two deaths. *Am J Trop Med Hyg* 1981;30:1141-3.
- Punyagupta S, Juttijudata P, Bunnag T. Eosinophilic meningitis in Thailand: clinical studies of 484 typical cases probably caused by *Angiostrongylus cantonensis*. *Am J Trop Med Hyg* 1975;24:921-31.
- Prociw P, Tiernan JR. Eosinophilic meningoencephalitis with permanent sequelae. *Med J Aust* 1987;147:294-5.
- Noskin GA, McMenamin MB, Grohmann SM. Eosinophilic meningitis due to *Angiostrongylus cantonensis*. *Neurology* 1992;42:1423-4.
- Kliks MM, Kroenke K, Hardman JM. Eosinophilic radiculomyeloencephalitis: an angiostrongyliasis outbreak in American Samoa related to ingestion of *Achatina fulica* snails. *Am J Trop Med Hyg* 1982;31:1114-22.
- Uchikawa R, Takagi M, Matayoshi S, Sato A. The presence of *Angiostrongylus cantonensis* in Vitu Levu, Fiji. *J Helminthol* 1984;58:231-4.
- Brown FM, Mohareb EW, Yousif F, Sultan N, Girgis NI. Angiostrongylus eosinophilic meningitis in Egypt. *Lancet* 1996;348:964-5.
- Nozais J-P, Moreau J, Morlier G, Kouame J, Doucet J. Premier cas de méningite à éosinophiles en Côte-d'Ivoire avec présence d'un *Parastrostrongylus* sp. dans le liquide céphalo-rachidien. *Bull Soc Pathol Exot* 1980;73:179-82.
- Petithory J, Jay M. Premier cas de méningite à éosinophiles à la réunion, probablement due à *Angiostrongylus*. *Bull Soc Pathol Exot* 1977;70:151-5.
- Renapurkar DM, Bhopale MK, Limaye LS, Sharma KD. Prevalence of *Angiostrongylus cantonensis* infection in commensal rats in Bombay. *J Helminthol* 1982;56:345-9.
- Heaton DC, Gutteridge BH. Angiostrongyliasis in Australia. *Aust N Z J Med* 1980;10:255-6.
- Tsai HC, Liu YC, Kunin CM, et al. Eosinophilic meningitis caused by *Angiostrongylus cantonensis*: report of 17 cases. *Am J Med* 2001;111:109-14.
- New D, Little MD, Cross J. *Angiostrongylus cantonensis* infection from eating raw snails. *N Engl J Med* 1995;332:1105-6.
- Pascual JE, Bouli RP, Aguiar H. Eosinophilic meningoencephalitis in Cuba, caused by *Angiostrongylus cantonensis*. *Am J Trop Med Hyg* 1981;30:960-2.
- Pascual Gispert JE, Aguilar Prieto PH, Galvez Oviedo MD. Hallazgo del *Angiostrongylus cantonensis* en el líquido cefalorraquídeo de un niño con meningoencefalitis eosinofílica. *Rev Cubana Med Trop* 1981;33:92-5.
- Martinez-Delgado JF, Gonzalez-Cortinas M, Tapanes-Cruz TR, Ruiz-Mendez A. Meningoencefalitis en Villa Clara (Cuba): estudio de 17 pacientes. *Rev Neurol* 2000;31:417-21.
- Barrow KO, Rose A, Lindo JF. Eosinophilic meningitis: is *Angiostrongylus cantonensis* endemic in Jamaica? *West Indian Med J* 1996;45:70-1.
- Eamsobhana P, Mak JW, Yong HS. Development of specific immunodiagnosis for human parastrongyliasis. In: Eamsobhana P, ed. Molecular biology and immunology in the diagnosis of parasitic diseases with emphasis on malaria. Bangkok, Thailand: Southeast Asian Medical Information Center, 1996:159-65.
- Nuamtanong S. The evaluation of the 29 and 31 kDa antigens in female *Angiostrongylus cantonensis* for serodiagnosis of human angiostrongyliasis. *Southeast Asian J Trop Med Public Health* 1996;27:291-6.
- Wilson M, Schantz P, Pieniazek N. Diagnosis of parasitic infections: immunologic and molecular methods. In: Murray PR, ed. Manual of clinical microbiology. 6th ed. Washington, D.C.: American Society for Microbiology, 1995:1159-70.
- Ko RC, Chiu MC, Kum W, Chan SH. First report of human angiostrongyliasis in Hong Kong diagnosed by computerized axial tomography (CAT) and enzyme linked immunosorbent assay. *Trans R Soc Trop Med Hyg* 1984;78:354-5.
- Ogawa K, Kishi M, Ogawa T, Wakata N, Kinoshita M. A case of eosinophilic meningoencephalitis caused by *Angiostrongylus cantonensis* with unique brain MRI findings. *Rinsho Shinkeigaku* 1998;38:22-6. (In Japanese.)
- Hwang KP, Chen ER. Clinical studies on angiostrongylus cantonensis among children in Taiwan. *Southeast Asian J Trop Med Public Health* 1991;22:Suppl:194-9.
- Yii CY, Chen CY, Chen ER, Hsieh HC, Shih CC. Epidemiologic studies of eosinophilic meningitis in southern Taiwan. *Am J Trop Med Hyg* 1975;24:447-54.
- Prociw P, Spratt DM, Carlisle MS. Neuro-angiostrongyliasis: unresolved issues. *Int J Parasitol* 2000;30:1295-303.
- Chotmongkol V, Sawanyawisuth K, Thavornpitak Y. Corticosteroid treatment of eosinophilic meningitis. *Clin Infect Dis* 2000;31:660-2.
- Lindo JF, Waugh C, Hall J, et al. Enzootic *Angiostrongylus cantonensis*

in rats and snails after an outbreak of human eosinophilic meningitis, Jamaica. *Emerg Infect Dis* (in press).

33. Aguiar PH, Morera J, Pascual J. First record of *Angiostrongylus cantonensis* in Cuba. *Am J Trop Med Hyg* 1981;30:963-5.
34. Andersen E, Gubler DJ, Sorenson K, Beddard J, Ash LR. First report of *Angiostrongylus cantonensis* in Puerto Rico. *Am J Trop Med Hyg* 1986;35:319-22.
35. Gardiner CHS, Wells S, Gutter AE, et al. Eosinophilic meningoen- cephalitis due to *Angiostrongylus cantonensis* as the cause of death in captive non-human primates. *Am J Trop Med Hyg* 1990;42:70-4.
36. Vargas M, Gomez Perez JD, Malek EA. First record of *Angiostrongylus cantonensis* (Chen, 1935) (Nematoda: Metastrongylidae) in the Dominican Republic. *Trop Med Parasitol* 1992;43:253-5.
37. Campbell BG, Little MD. The finding of *Angiostrongylus cantonensis* in rats in New Orleans. *Am J Trop Med Hyg* 1988;38:568-73.
38. Steffen R, Collard F, Tornieporth N, et al. Epidemiology, etiology, and impact of traveler's diarrhea in Jamaica. *JAMA* 1999;281:811-7.

Copyright © 2002 Massachusetts Medical Society.